

**PATIENT**

Chief Heckman

**SPECIES**

Feline

**BREED**

DSH

**SEX**

Male Neutered

**AGE**

8 years

**WEIGHT**

12.5lbs

**INTERPRETED BY**

Maggie Machen  
Lamy, DVM, DACVIM  
(Cardiology)

**IMAGING PERFORMED BY**

Sara Hansen

**HOSPITAL NAME**

Albany Animal  
Hospital

**REFERRING VET**

Dr. Spangler

**INVOICE**

28570

**DATE**

1/25/23

**PRESENTING CLINICAL SIGNS**

History: Grade 3/6 heart murmur. ProBNP: 708.

**ECHOCARDIOGRAM FINDINGS**

2D, m-mode, color flow and doppler imaging is available. The left ventricular wall is irregular with regions of mild hypertrophy and a focal septal bulge. Adequate systolic function. There is a diffusely hyperechoic endocardium consistent with fibrosis. The papillary muscles are remodeled and mildly enlarged. The mitral valve is normal with no obvious MR. The left atrium is mild to moderately dilated and bulbous in appearance. No obvious smoke. The right atrium is normal. Tricuspid valve is normal with no TR. The right ventricle appears normal. Blood flow through both the LVOT and RVOT is normal in velocity. No pericardial effusion seen. No pleural effusion. No obvious cardiac tumors.

**CARDIAC CHART**

FELINE CARDIAC PARAMETERS	BODY WEIGHT (kg)	HR (BPM)	IVSd (cm) (Moise, Pipers)	LVIDd (cm) (Moise, Pipers)	LWWd (cm) (Moise, Pipers)	FS (%)	EF (%)
NORMAL PARAMETER	-----	150-240	0.35-0.55	<2 (mean 1.5)	3.5-0.55	35-67	80-100
PATIENT	5.7		0.71	1.4	0.60NM	52	85
FELINE CARDIAC PARAMETERS	LA/AO (Boon)	LA/AO HEART BASE (Swe) (Abbott)	LA 2D short axis Base view (cm) (Abbott)		LVOT VEL (m/s)	RVOT VEL (m/s)	E max (m/s)
NORMAL	<1.5	<1.3	<1.2		<1.6	<1.3	<0.9
PATIENT	1.4	1.55	1.55		0.96	0.9	NM

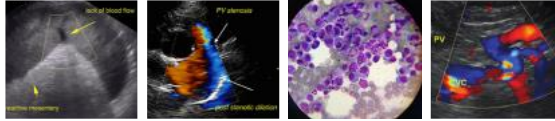
*\*Note: All measurements based upon multi-modal images and methods. An average value is reported.*  
Adapted from June Boon, Veterinary Echocardiography, 1998  
Abbott J & MacLean H JVIM 2006;20: 111-119, Moise et al. Am J Vet Res 47:1476, 1986. Pipers et al. Am J Vet Res 40:882, 1979.

**INTERPRETATION OF THE FINDINGS & FURTHER RECOMMENDATIONS**

The finding of left atrial enlargement in the face of irregular LV wall thickening may be consistent with Hypertrophic Cardiomyopathy; however, an Unclassified Cardiomyopathy (UCM), is also possible with only mild LV changes. Mild to moderate left atrial dilation is present, suggesting risk for complication going forward. No additional issues are identified and no cause for the murmur is visualized.

Regardless of categorical classification, the finding of left atrial dilation confers risk for progression in the future and medications should be considered even without symptoms. Close monitoring of RR/RE is advised at home. Pimobendan can be considered if the patient is easily medicated. Additionally, Plavix may be reasonable given atrial dilation to help decrease the risk of a blood clot event in the future. In an asymptomatic cat, if there is difficulty or reluctance to medicate at home it is reasonable to simply monitor going forward.

The long-term prognosis given the totality of the findings is guarded; however, there is a highly variable rate of progression in cats with subclinical disease. There will always remain risk for progression to CHF and development of blood clots and/or sudden death in the future.



**PATIENT**

Chief Heckman

Monitoring is certainly advised, particularly should any respiratory signs, collapse or significant lethargy be noted in the future.

**SPECIES**

Feline

Anesthetic risk is considered mild if needed. Cardiac protective drug choices (opioid/benzodiazepine premedication, propofol or alfaxalone induction, isoflurane gas) are recommended. Pre-oxygenate for 5-10 minutes prior to induction. Monitor for arrhythmias, hypotension, and hypoxia both intra and post-operatively and intervene as necessary. Mild IV fluid restriction is recommended to avoid fluid overload. Avoid heart rate stimulating drugs such as atropine unless clinically indicated.

**BREED**

DSH

**SEX**

Male Neutered

**PLAN**

Screening BP and T4 are recommended every 6 months. If elect to medicate, oral medications are as follows: Institute blood thinner Clopidogrel (Plavix) 75mg tablets; give ¼ tab orally once daily (NOTE: this medication is very bitter on the cut edges). Institute off label Pimobendan 1.25mg PO q12h.

**AGE**

8 years

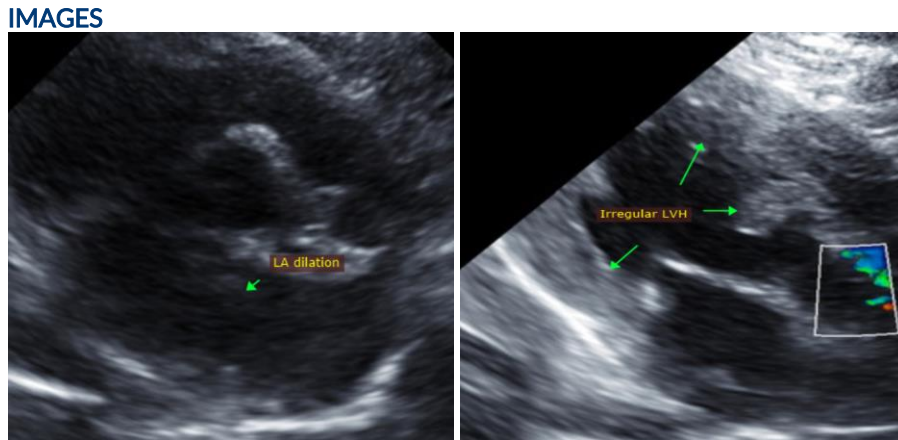
A recheck echocardiogram is recommended in 6 months to assess progression.

**WEIGHT**

12.5lbs

**INTERPRETED BY**

Maggie Machen Lamy, DVM, DACVIM (Cardiology)



**IMAGING PERFORMED BY**

Sara Hansen

**HOSPITAL NAME**

Albany Animal Hospital

The information and recommendations provided are based on the images presented by the referring veterinarian. No evaluation can be communicated regarding pathology that was not visible in the image/video clips provided.

**REFERRING VET**

Dr. Spangler

Thank you for this referral. This report was generated using transcription software, and minor dictation errors may be present. If the clinical or image interpretation does not parallel your findings or if I can be of any further assistance, please contact me.

**INVOICE**

28570

**Maggie Machen Lamy, DVM**  
Diplomate of the American College of Veterinary Internal Medicine (Cardiology)  
info@sonopath.com

**DATE**

1/25/23